

Rehabilitation of young children after loss of central incisors due to a TDI with the two-phase transplantation concept - a case report

Authors:

Surian Herrmann¹

Karin Christine Huth²

Matthias Widbiller³

Dirk Nolte^{1,4}

Author's institutional affiliations:

¹Clinic for Oral and Maxillofacial Surgery, Munich, Germany

² Department of Conservative Dentistry and Periodontology, University Hospital LMU Munich

³ Department of Conservative Dentistry and Periodontology, University Hospital Regensburg,

⁴Ruhr-University of Bochum

Corresponding authors:

Dr. Surian Herrmann
MKG MUC - Clinic for Oral and Maxillofacial Surgery
Sauerbruchstraße 48, 81377 München
E-mail: surian.herrmann@gmail.com

Prof. Dr. Dr. Dirk Nolte
MKG MUC - Clinic for Oral and Maxillofacial Surgery
Sauerbruchstraße 48, 81377 München
E-mail: dirk.nolte@kmg-muc.com

Abstract

Background: The treatment of lost permanent incisors in children and adolescents, due to a consequence of a TDI is a difficult task for all areas of modern dentistry. The two-phase autotransplantation (autoTX) concept allows rapid management of tooth loss in young children and adolescents (age: 6 to 16). **Case presentation:** A nine-year-old boy presented with loss of upper permanent central incisor in early mixed dentition (6 to 10 years, phase I). The not yet fully resorbed primary canine was used as primary tooth transplant for the lost incisor. The intentional renounce on endodontic treatment of the primary transplant permits natural exfoliation of the transplant occurring either spontaneously or due to undermining resorption through the adjacent erupting teeth. Primary tooth transplants have a mean survival rate of 7,2 years. In the late mixed dentition (10 to 16 years, phase II), the primary tooth transplant is electively removed and replaced by a premolar autoTX for long-term rehabilitation of the meanwhile adolescent patient. **Results:** Primary canine autoTX acts as a temporary treatment with instant surgical gap closure. Ensuing premolar autoTX in phase II then acts as permanent denture with excellent survival rates of 93% to 100%. **Conclusions:** The “TPTX” concept is a surgical approach that immediately restores the patient’s function and aesthetics after tooth loss in early childhood supporting the growth of local bone and soft tissue in the growing adolescent jaw, thus even allowing sufficient implantation after concluded growth of the jaw ended in case of loss of the permanent premolar transplant.

1. Introduction

The treatment of lost permanent incisors in children and adolescents, due to a consequence of a traumatic dental injury (TDI) is a difficult task for all areas of modern dentistry.

The prevalence for TDI in permanent and in the primary dentitions is reported to be as high as 15-30%.¹

In case of loss of a permanent incisor in childhood and adolescence there are different therapy options. In most cases implants are recommended only after bone growth has been completed.² Partial dentures need follow up adjustments and, like resin-bonded fixed dental prosthesis, lead to the need for augmentation prior to subsequent implant placement, as the local bone atrophies due to the lack of loading.³ Orthodontic gap closure has a narrow indication or results in loss of esthetics.³ The autogenous tooth transplantation of, for example, a premolar into the gap of the permanent incisor represents a reliable alternative therapy.³ In this context, the autogenous tooth transplantation not only allows the alveolar ridge to be preserved without impeding growth, but also represents both a functional and esthetic therapy after resin-adhesive buildup.⁴ Success rates of 84% to 94% and survival rates of 93% to 100% have been reported.⁴⁻⁶ As with avulsed teeth, success of autogenous tooth transplantation depends largely on periodontal healing of the autotransplant.⁶

However, if anterior tooth trauma occurs before the donor tooth has reached a sufficient root length, the transplantation of a primary tooth with a mean survival rate of 7,2 years can be used.⁷ Depending on the time of the TDI, there is a possibility that implant placement may still not be indicated prior to loss of the primary tooth transplant.

Since anterior TDI occurs in the primary and early mixed dentition (between six and ten years of age) and in the late mixed dentition (10 to 16 years of age), we have developed a concept that gives the clinical practitioner a therapy that covers both phases of dentition referred to as “two-phase transplantation” (TPTX) concept (Figure 1). For this purpose, the not yet fully

resorbed primary teeth, preferably the primary canines, are used in the primary and early mixed dentition as autogenous transplants for replacement of the upper central incisors (phase I: primary (canine) tooth transplantation).

The procedure represents a biological approach by the intentional renounce on endodontic treatment, thus basing on the natural exfoliation of the transplanted primary tooth. This approach is therefore temporarily allowing immediate posttraumatic aesthetic rehabilitation of the traumatized patient up to the age of 10 to 16 years which has been proven effective to support both bone and soft tissue growth in the adolescent patient.^{8,9}

In the late mixed dentition (phase II, >10 years), when autoTX of primary teeth is no longer available or natural exfoliation of primary tooth transplants is to be expected, we apply the well-documented technique of premolar autoTX as permanent therapy.¹⁰

2. Case Report

A nine-year-old boy lost a root-fractured upper right central incisor in a swimming accident at a lakeside and injured the upper left incisor with an uncomplicated crown fracture. The coronal part of the fractured tooth 11 could not be found in the lake and thus it was not possible to replant it. The patient presented three months after the accident with the following findings (Figure 2): The clinical situation showed a missing tooth 11 and the reconstructed incisal edge of tooth 21 with a composite build-up (Figure 2/A). The actual orthopantomogram (OPG) shows initial situation with the root-fractured tooth 11 before removal of the residual root by the local dentist and the uncomplicated crown fracture of the tooth 21 (Figure 2/B). All four primary canines show reduced root lengths due to the natural exfoliation by the breakthrough of the permanent canines.

On demand of the orthodontist's planning, we extracted all four primary canines and decided to use the primary tooth 63 as primary autotransplant since it showed the longest root of the four primary canines. Tooth 63 was then autotransplanted into the defective gap at position 11 according to the technique described below and fixed with a wire-composite semi-rigid splint to the neighboring tooth 12 for two weeks (Figure 2/C). Figure 2/D shows the situation three weeks later directly after removal of the titan trauma splint with one resorbable suture still left in situ.

The primary tooth transplant 63 remained functional in situ for 4,5 years until the patient's age of 13 years. Figure 3 shows the postoperative radiological and clinical findings 4.5 years (A/B) after transplantation, respectively. The exfoliation of the root did not make significant progress over time, which may be attributed to the lack of an erupting upper adjacent tooth. Meanwhile the natural breakthrough of the permanent canines had taken place (Figure 3/B). No aesthetic or functional deficiency is notable, vertical bone growth appears good which is reflected by an even overshooting projection of the gingival margin at the trauma site 11 relative to the healthy adjacent tooth 21 (Figure 3/A and 3/B). Aesthetic correction of the primary canine with adhesive composite filling or bleaching was neither desired by the patient nor his parents since they were happy with the present situation. The patient did not suffer from pain or discomfort at any time. The transplant showed no mobility and was fully functional. Root canal treatment with $\text{Ca}(\text{OH})_2$ was not necessary at any time. At the age of 13.5 years, the patient presented again at the clinic for decision-making of the consecutive therapy.

In consultation with the treating orthodontist, we enrolled the patient in phase II of the "TPTX" concept by applying premolar autoTX. Due to the gnathological situation, the orthodontist decided to use tooth 25 as transplant in region 11. Figure 4/A shows the

postoperative x-ray of the patient after autoTX 25 to 11 on the day of surgery: The primary canine transplant was electively extracted and the premolar 25 was transplanted after preparation and extension of the alveolar pocket in region 11. The transplant was fixed to the orthodontic wire with composite and the soft tissue was adapted by two mattress sutures (Figure 4/B). During the operation it turned out that the premolar was twin-rooted, which significantly complicated its positioning in region 11 intraoperatively. To avoid interfering occlusal contacts, the tooth was placed in slight infraposition so that subsequent orthodontic rotation and extrusion of the tooth could be performed undisturbedly. The transplant itself was bracketed by the orthodontist three weeks after removing the composite fixture from the orthodontic bar and left in this position for another three weeks without active movement. Six weeks after surgery the orthodontist was allowed to start with gradual rotation of the palatal cusps out of the occlusal contact of the opposing teeth. Figures 5/A and B show the initial rotation of transplant position three month after surgery. Figure 6/A shows the final result. The premolar transplant has meanwhile been built up in composite adhesive technique. There is a substantial win of soft tissue height on the transplant side (tooth 11) as compared to the left upper incisor with the “uncomplicated” crown fracture (tooth 21). Figure 7 shows the clinical (7/A) and radiological (7/B) findings eight years after autoTX 25 to 11, gingivectomy of the soft tissue surplus to achieve an aesthetic correction of the autotransplant was again not desired by the patient. The autoTX 25 serves as permanent replacement for the lost tooth 11.

3. Discussion

The two-phase transplantation concept (“TPTX” concept) represents a surgical approach that ultimately arose from the absence of therapeutic alternatives aiming at a quick and sustainable treatment of traumatic dental injury in young children and adolescents.

The “TPTX” concept allows a rehabilitation both in the primary and early mixed dentition at the age between six and 14 years (Figure 1). In a retrospective study with a total of 40 patients and 53 primary canine autotransplants, Hoss et al. demonstrated the development of soft tissue and bone in the adolescent jaw and a mean survival rate of 86 months (7.2 years) of the primary autotransplants.⁷ We know so far of no therapy in the current literature that uses the natural exfoliation of transplanted primary teeth for the induction of local bone and soft tissue growth. The technique permits reliable and immediate prosthetic, aesthetic and functional rehabilitation of the young patients (Figure 2(A)) which is associated with high acceptance by patients and parents.⁷

Autotransplantation of primary (canine) teeth does not necessarily require root canal filling of the transplant. Only in the event of an inflammatory complication is it necessary to fill the tooth with Ca(OH)₂ thus allowing further physiological resorption. Aiming at the natural resorption of the primary tooth transplants, we recommend to use only resorbable root canal fillings.

If the young patients with TDI successfully pass phase I of the “TPTX” concept and reach 10 to 14 years of age, the intervention can be regarded as success according to our understanding. Thereafter, we recommend our patients ensuing autogenous premolar transplantation (phase II) as a well-established and successful long-term therapy as shown in this case report. The technique of premolar transplantation provides excellent long-term results.⁴⁻⁶

4. Conclusion

The “TPTX” concept represents a new surgical approach that allows immediate restoration of the patient’s function and aesthetics after tooth loss in early childhood supporting the growth of local bone and soft tissue in the growing adolescent jaw. Therefore, an interdisciplinary workflow between surgeon, orthodontist and general dentist is necessary.

Ethical Approval

This study was approved by the ethical committee of the Bavarian Medical Association of Munich, number 13116/2013. We confirm that the guidelines of this study have followed the Declaration of Helsinki. Informed consent of the patient has been obtained before publication.

Conflict of Interest

The corresponding author confirms that no conflict of interest exists for himself or his/her co-authors.

References

1. Petti S. Over two hundred million injuries to anterior teeth attributable to large overjet: a meta-analysis. *Dent Traumatol*, 2015; 31: 1-8.
2. Bohner L, Hanisch M, Kleinheinz J, Jung S. Dental implants in growing patients: a systematic review. *Br J Oral Maxillofac Surg*. 2019; 57(5): 397-406.
3. Schwartz-Arad D, Levin L, Ashkenazi M. Treatment options of untreatable traumatized anterior maxillary teeth for future use of dental implantation. *Implant Dent*. 2004;13(2): 120-8.
4. Atala-Acevedo C, Abarca J, Martínez-Zapata MJ, Díaz J, Olate S, Zaror C. Success Rate of Autotransplantation of Teeth With an Open Apex: Systematic Review and Meta-Analysis. *J Oral Maxillofac Surg*. 2017; 75(1): 35-50.
5. Andreasen JO, Paulsen HU, Yu Z, Bayer T, Schwartz O. A long-term study of 370 autotransplanted premolars. Part II. Tooth survival and pulp healing subsequent to transplantation. *Eur J Orthodont*. 1990; 12: 14-24.
6. Akhlef Y, Schwartz O, Andreasen JO, Jensen SS Autotransplantation of teeth to the anterior maxilla: A systematic review of survival and success, aesthetic presentation, and patient-reported outcome. *Dent Traumatol*. 2017; 00: 20– 27.
7. Hoss F, El-Mahdy K, Linsenmann R, Franz C & Nolte D. Primary tooth autotransplantation: update and retrospective clinical study, *Acta Odontologica Scandinavica*, 2021; 79(8): 582-592.
8. Pohl Y, Geist P & Filippi A. Transplantation of Primary Canines after Loss or Ankylosis of Upper Permanent Incisors. A prospective Case Series Study on Healing and Survival. *Dental Traumatology*, 2008; 24: 388-403.
9. Tschammler C, Angermair J, Linsenmann, R, Heiligensetzer M & Nolte D. Primary Canine Auto-Transplantation - A New Surgical Technique. *Oral Surgery, Oral Medicine, Oral Pathology, Oral Radiology*, 2014; 119: 158-169.
10. Waldon K, Barber SK, Spencer RJ & Duggal MS. Indications for the Use of Auto-Transplantation of Teeth in the Child and Adolescent. *European Archives of Paediatric Dentistry*, 2012; 13: 210-216.

Figures

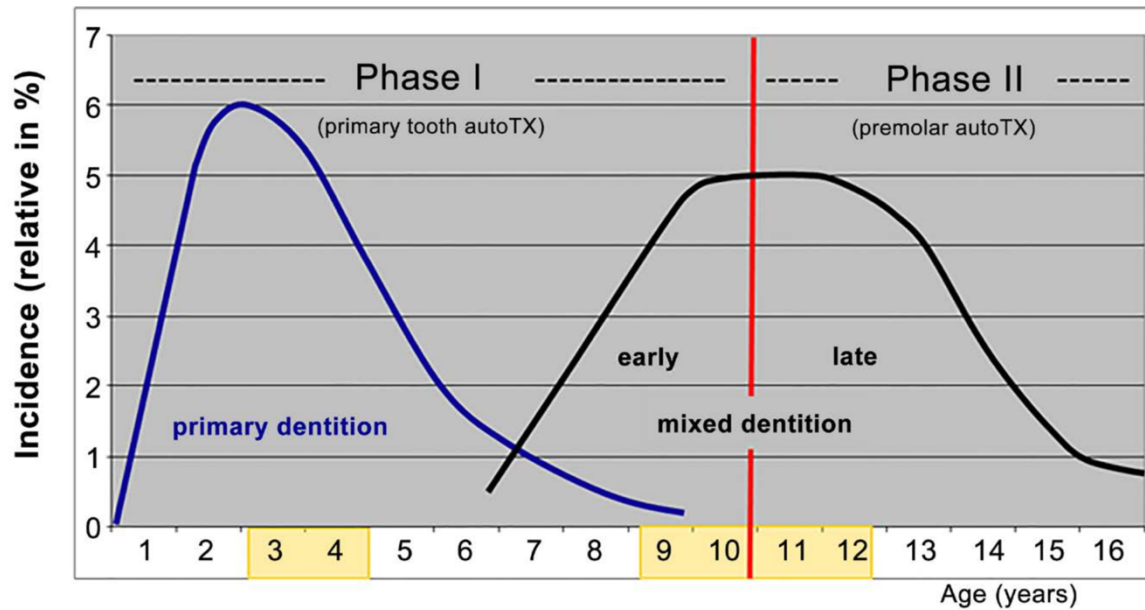


Figure 1. Two-phase transplantation concept (“TPTX” concept) taking into account the peak incidence of occurrence of TDI in childhood and adolescence (yellow timeline). Left of the red line comprises phase I in which primary (canine) tooth autotransplantation (autoTX) is recommended as the preferred temporary therapy, right of the red line indicates phase II in which premolar autoTX is recommended as permanent (lifelong) therapy.

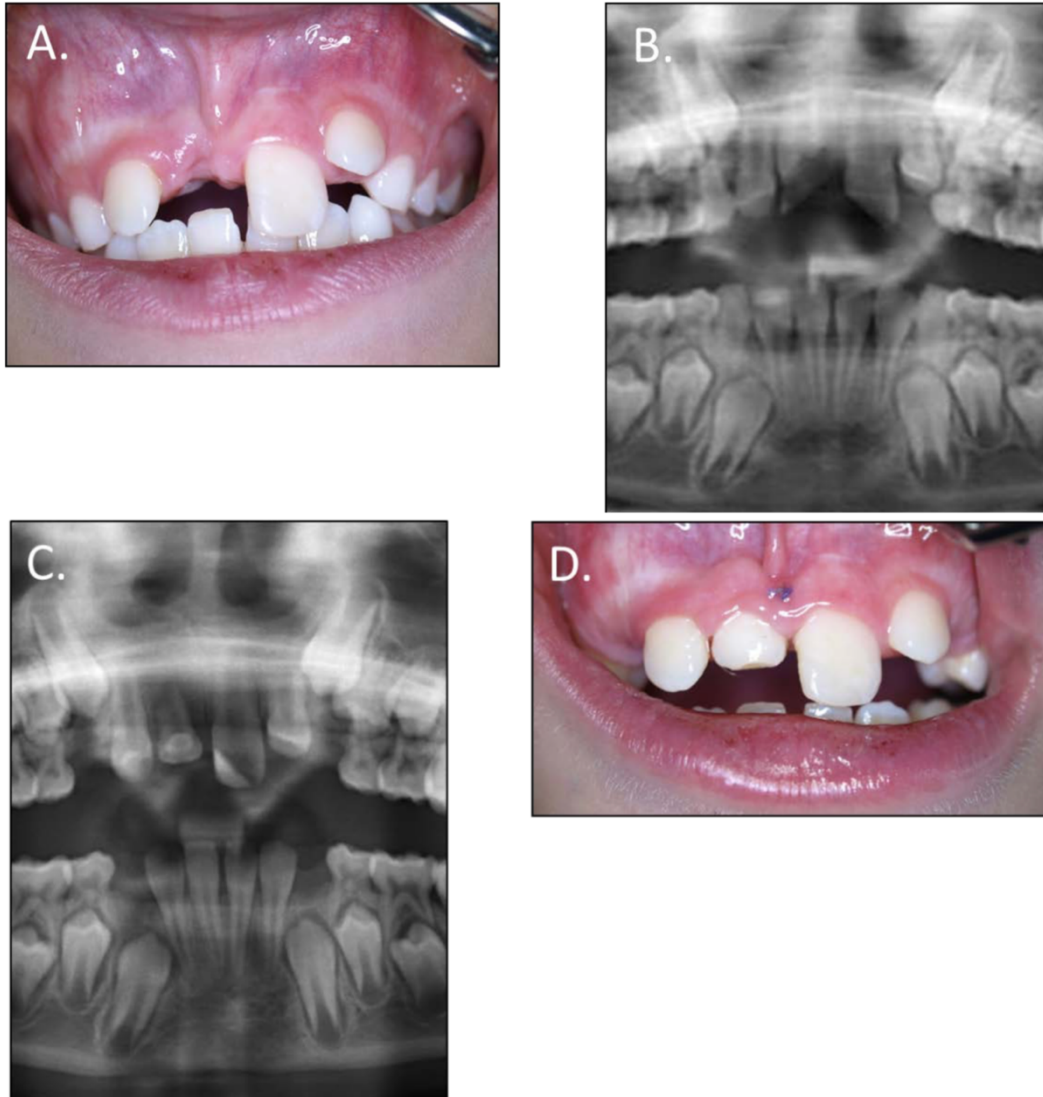


Figure 2. Clinical case of nine-year-old boy after root fracture and loss of tooth 11 associated with uncomplicated crown fracture of tooth 21 after swimming accident. (A) Post-traumatic clinical situation with tooth gap in region 11 with evidence of vertical and horizontal tissue deficit. Incisal edge of tooth 21 was reconstructed with a composite build-up. (B) Post-traumatic orthopantomogram with root fractured tooth 11 and crown fracture 21 (not yet restored). Fractured root of tooth 11 here still in situ has later been removed by the local dentist. All primary canines show already resorption of their roots to approximately 50-60% of total length. (C) Post-operative orthopantomogram directly after autogenous transplantation of primary canine 63 to 11. The semi-rigid splint on the tooth is visible, the transplant is placed in clear infraposition. Note the already marked reduction of root length of the transplanted tooth 63. (D) Clinical situation three weeks after autoTX 63 to 11 and splint removal. One resorbable suture is still in situ.

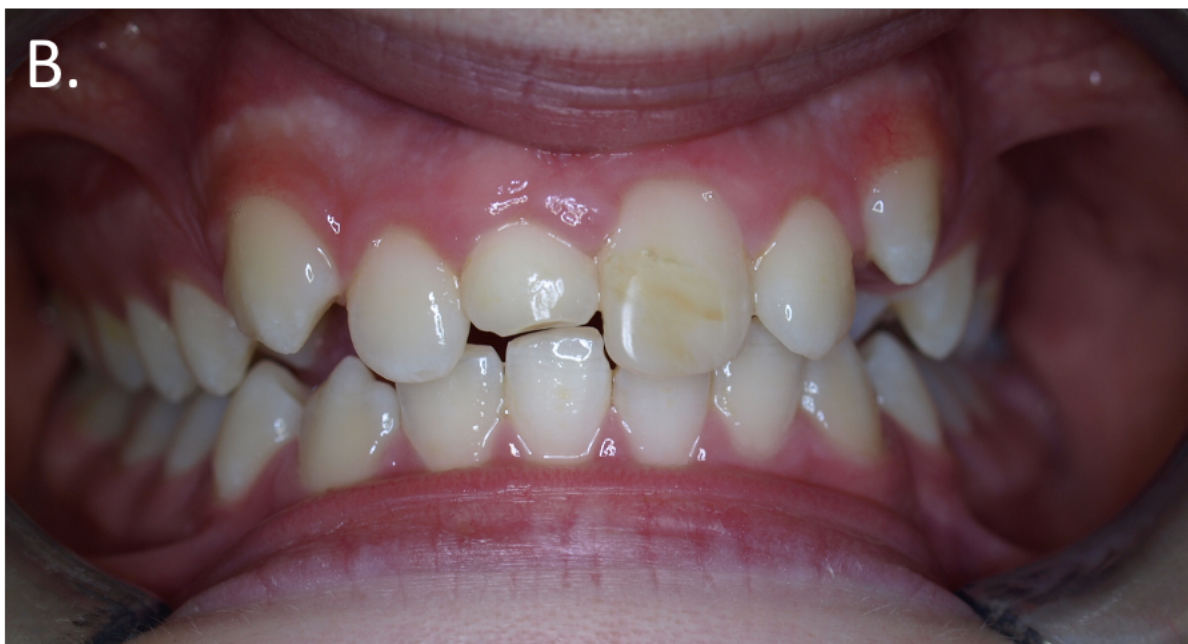
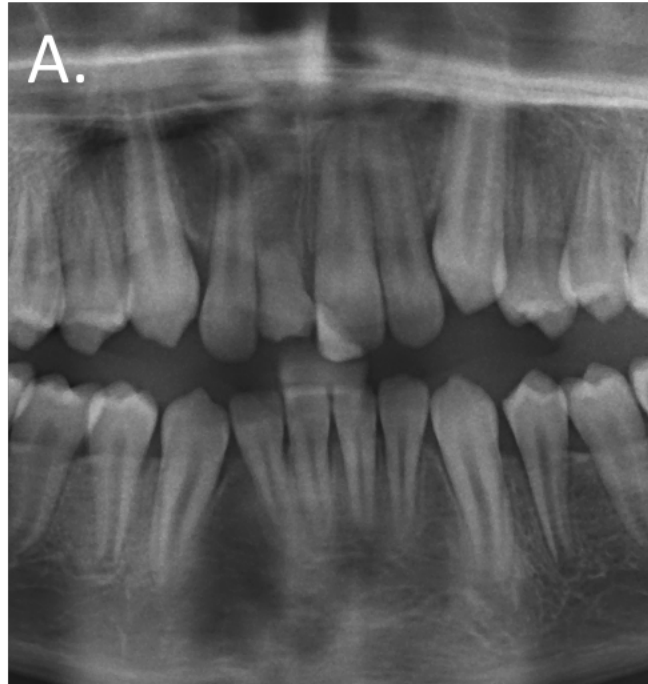
Figure 3. (A) Radiological and (B) clinical situation 4.5 years post-TX 63 to 11 (phase I of “TPTX” concept). Over the follow-up of 4.5 years, the co-development of the alveolar process and soft tissue in region 11 is clearly visible. The contemporary breakthrough of the neighboring teeth 13, 12, 22, 23 is to be seen. The partial resorption of the root of the primary canine in position 11 documents the biological behavior of the transplant. Ankylosis with vertical growth inhibition is not visible as indicated by the maintenance of vertical soft tissue growth as compared to healthy tooth 21.

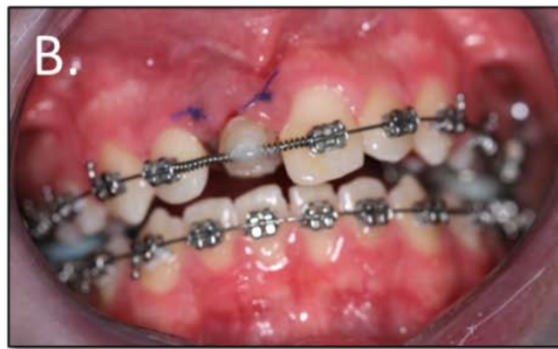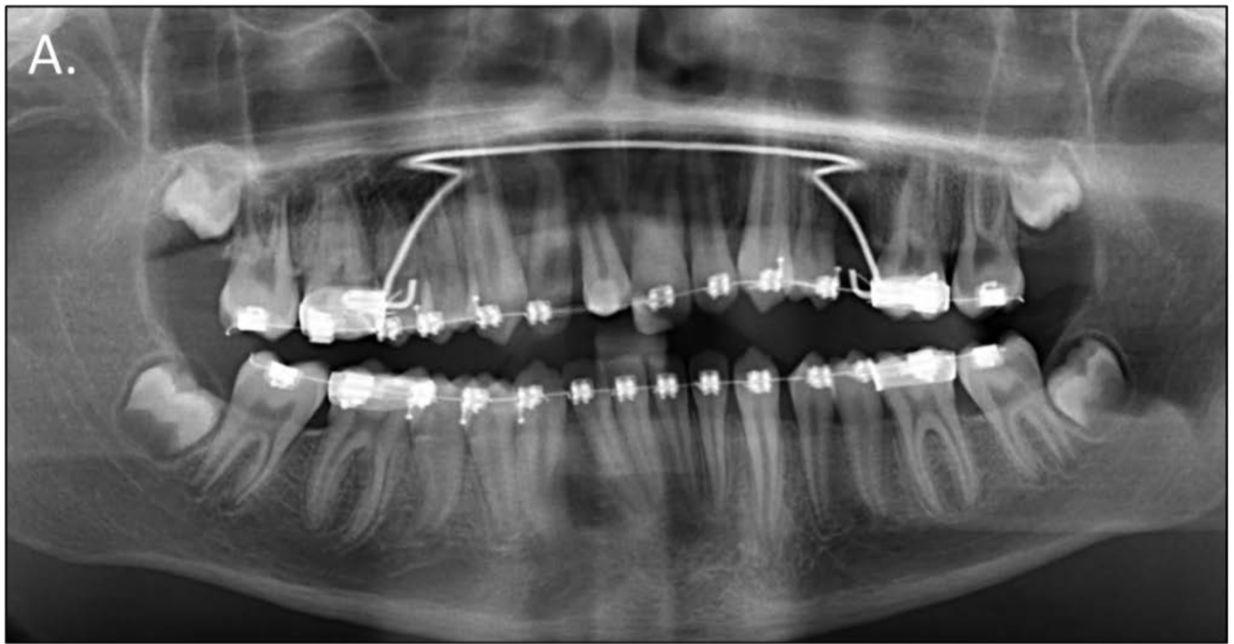


Figure 4. (A) Radiological and (B) clinical situation of the meanwhile 14 years old boy directly after premolar autotransplantation 25 to 11 (phase II of “TPTX” concept). The primary canine tooth transplant was extracted and premolar 25 was transplanted in position 11. The empty extraction socket in regio 25 is visible. To avoid interfering occlusal contacts the tooth was positioned in infraposition for subsequent rotation and extrusion by the orthodontist. The transplant was fixed with composite to the orthodontic bow, the mucosal flap was readapted by two vertical mattress sutures.

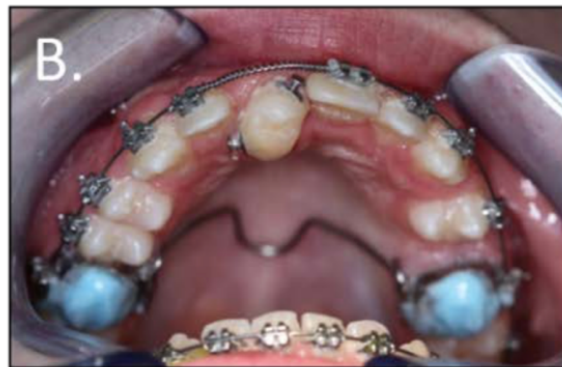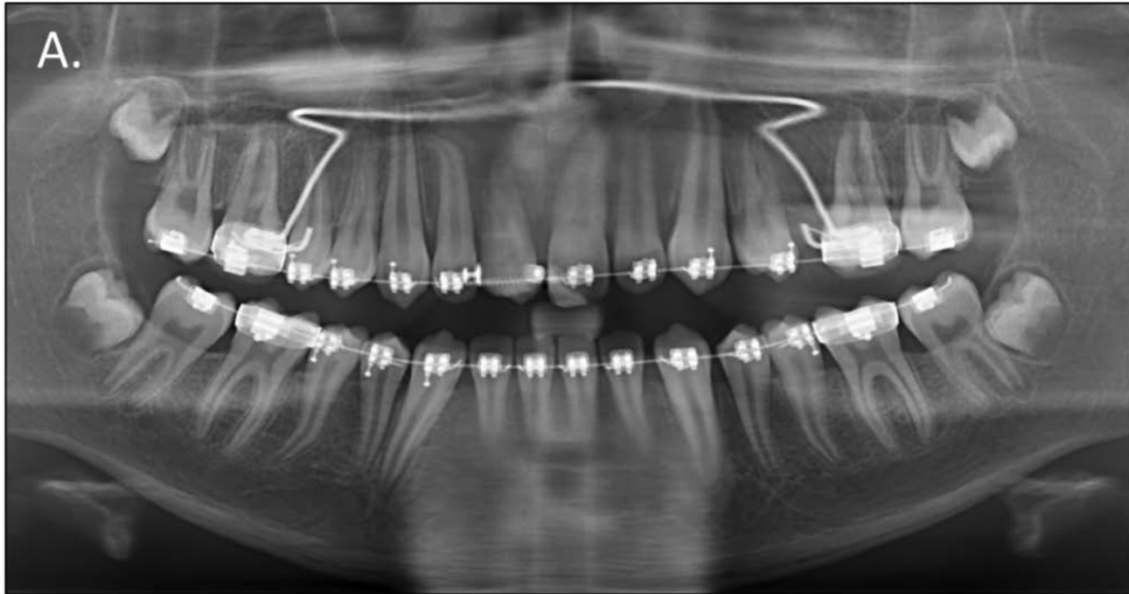


Figure 5. (A) Radiological and (B) clinical follow-up three months after premolar autoTX 25 to 11 (phase II of TPTX-concept). The transplant has meanwhile been bracketed by the orthodontist to start derotation and extrusion of the transplant. Two brackets have been fixed mesially and distally of the crown to facilitate the rotation of the transplant.

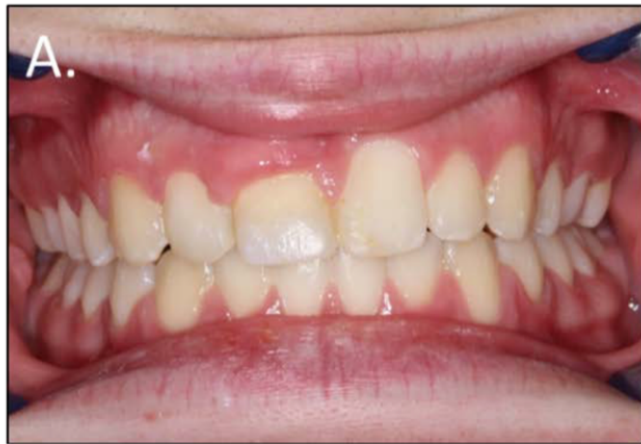

Figure 6. (A) Clinical situation 2.5 years after finishing orthodontic therapy and the restoration of autotransplant 11 in composite adhesive technique with a clear soft tissue surplus compared to tooth 21.

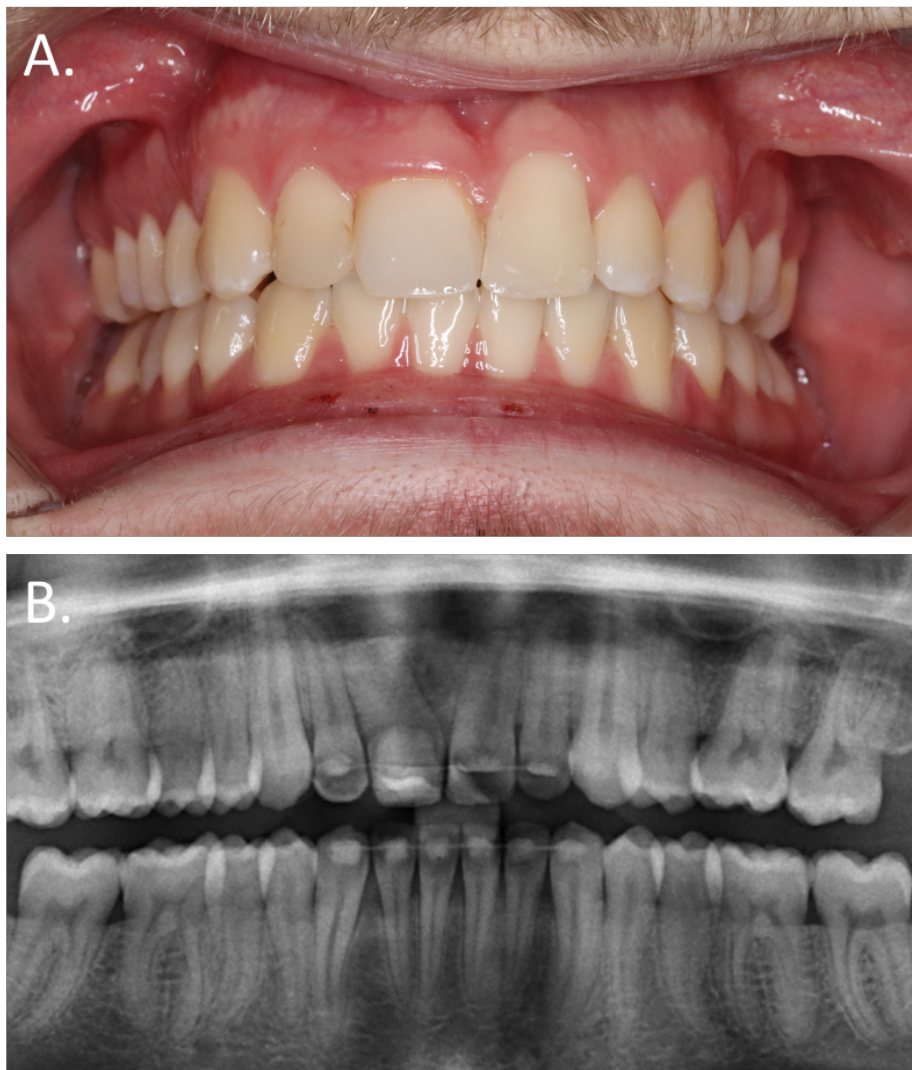


Figure 7. (A) Clinical and (B) radiological situation eight years after autoTX.